

# Case 8

**Dr. Preesha Balan**

(MD,DNB,FRCPath)

Clinical Associate

Sir. H.N. Reliance Foundation Hospital and Research Centre



- 67/M
- Weight loss, vague abdominal pain and progressive jaundice.
- **Bilirubin -8.67 mg/dl**
- **CA 19-9- 314.2 U/ml, CEA- 117 ng/ml**
- **CT Scan** – Periapillary mass lesion with dilated IHBR in the lower CBD. Prominent pancreatic duct with lymph nodes in the locoregional territory and small bowel mesentery.
- **Endoscopy**- Proliferative lesion in second part of duodenum close to the ampulla.
- **Biopsy**- Moderately differentiated adenocarcinoma.



- Exploratory laparotomy for an intended pancreatico-duodenectomy / palliative bypass subject to the intra operative findings
- Large conglomerate lymph nodal mass identified in the small bowel mesentery measuring 5-7 cms, abutting and closing in on the root of the small bowel mesentery close to the main mesenteric vasculature



- Additionally, along the anti mesenteric border of the first loop of the jejunum, (about 10 cms from the DJ flexure ), a nodular exophytic lesion was observed, which felt firm on palpation.
- 1 cm on its external aspect and seemed to have a full thickness invasion across the jejunal wall .

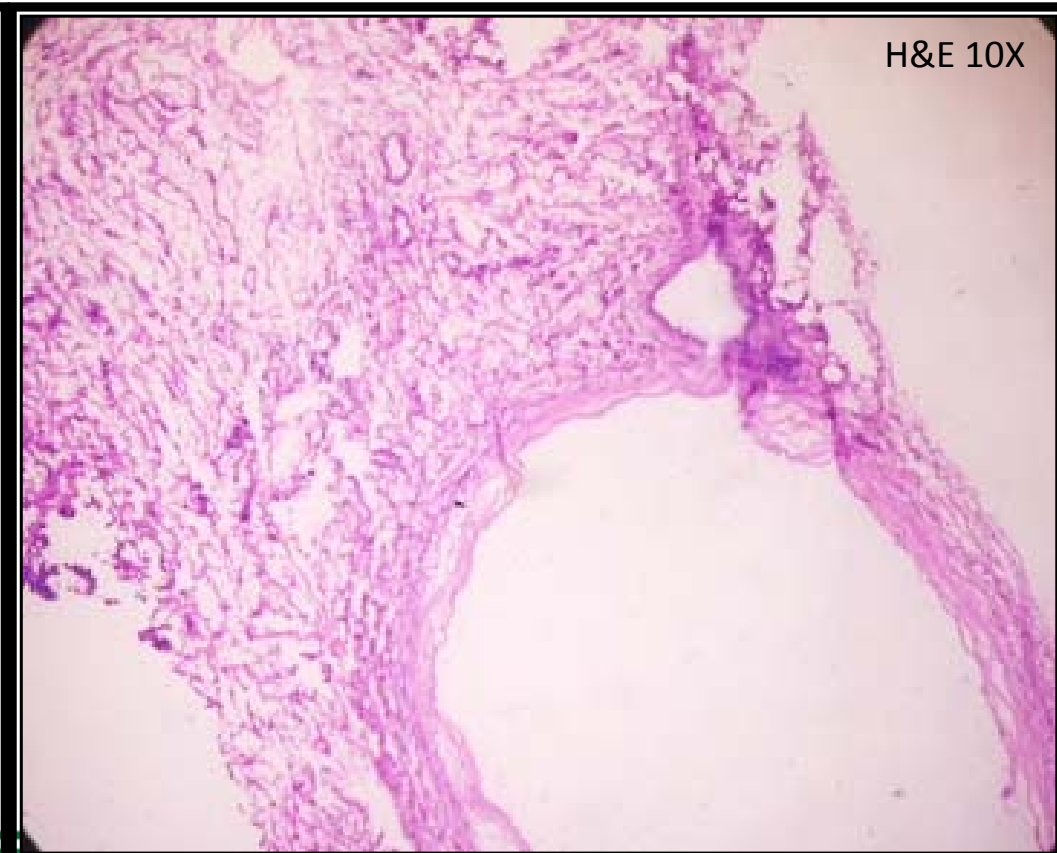
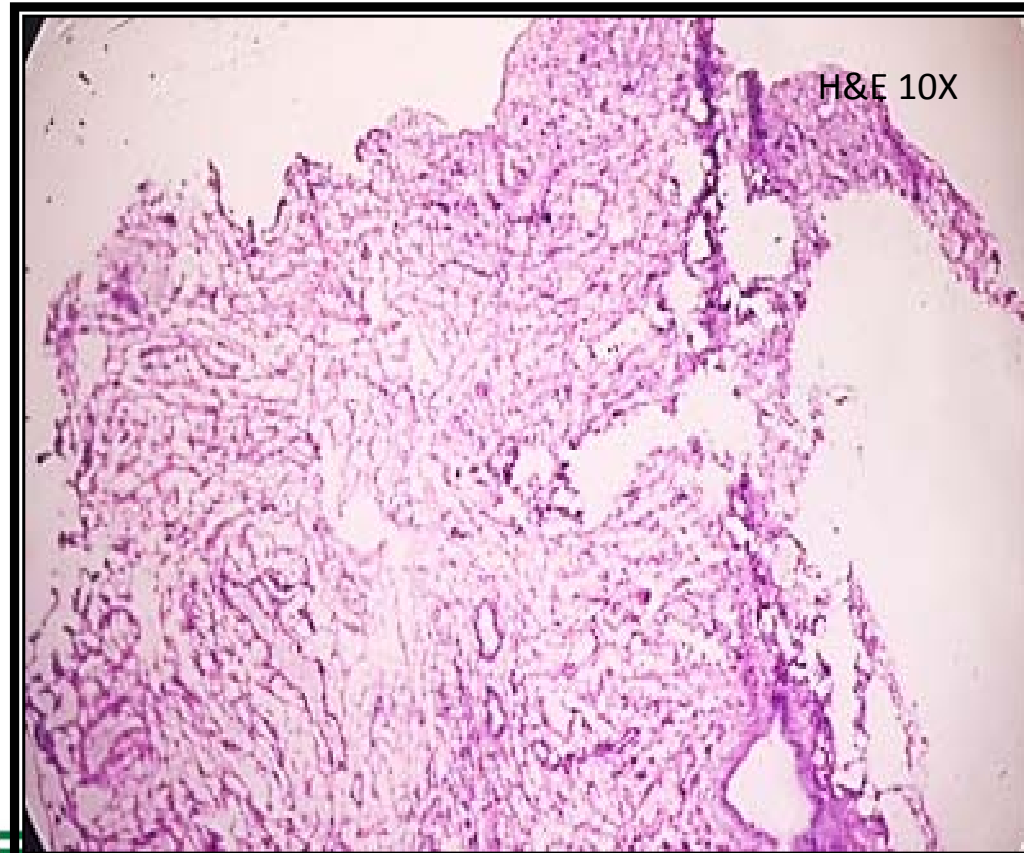


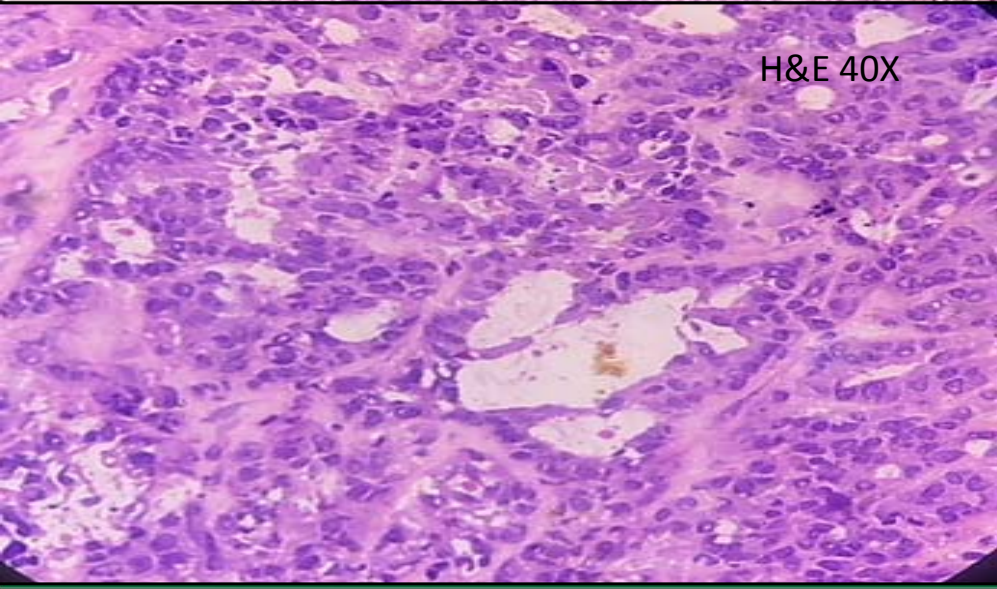
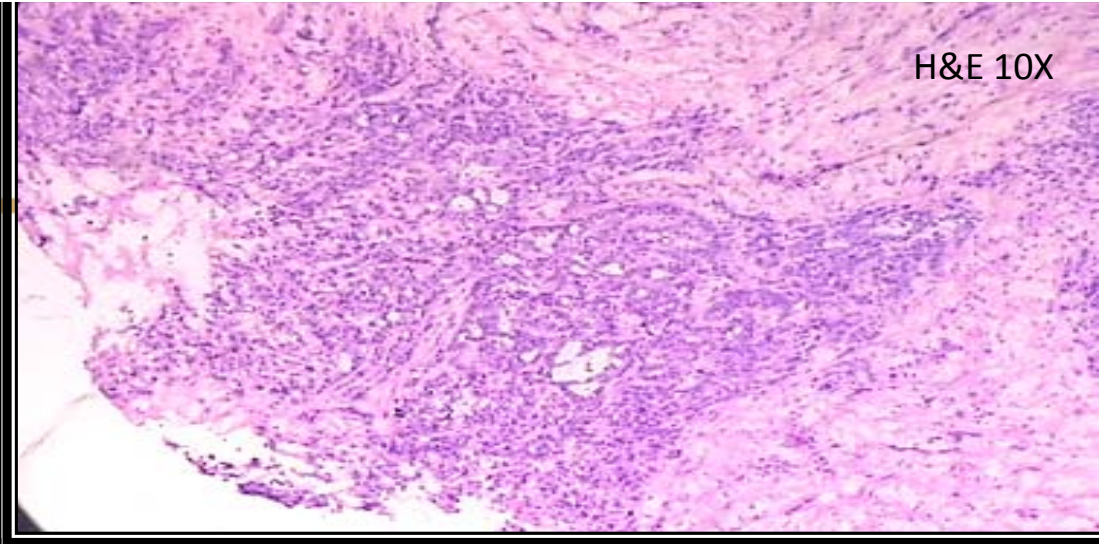
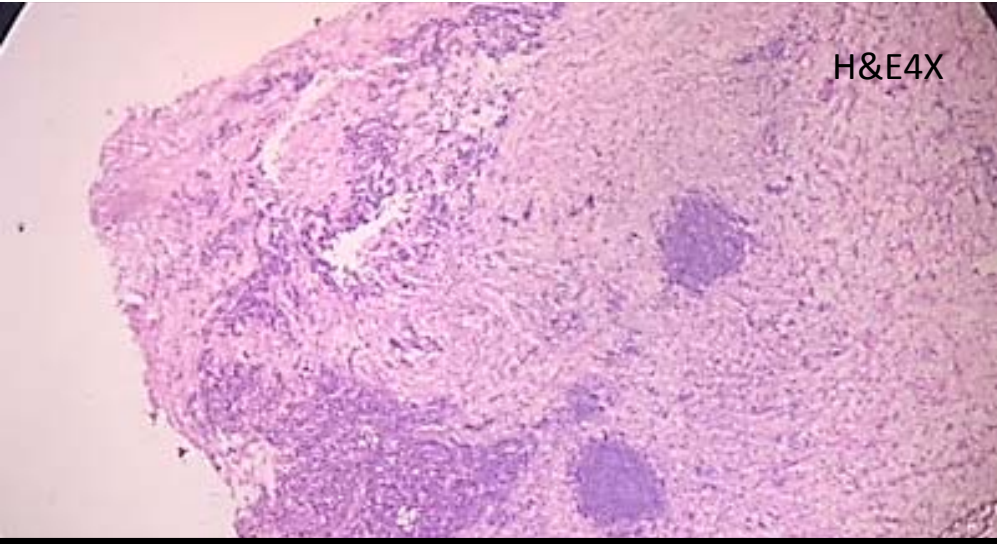
The lesion was not typical of

- Metastatic deposit
- Neuroendocrine lesion
- GIST
- Primary adenocarcinoma of the jejunum ( a rare condition )



# Nodule on Gall Bladder

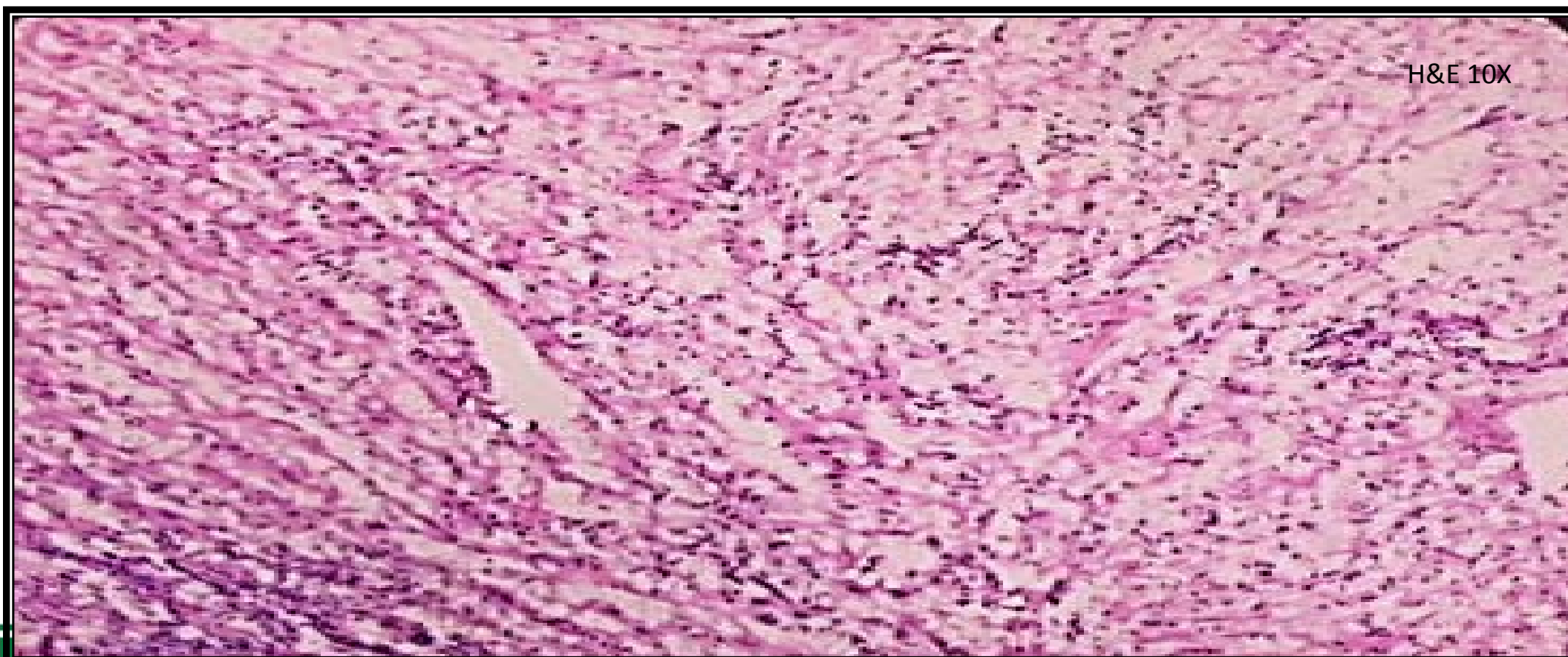




## Mesenteric nodule



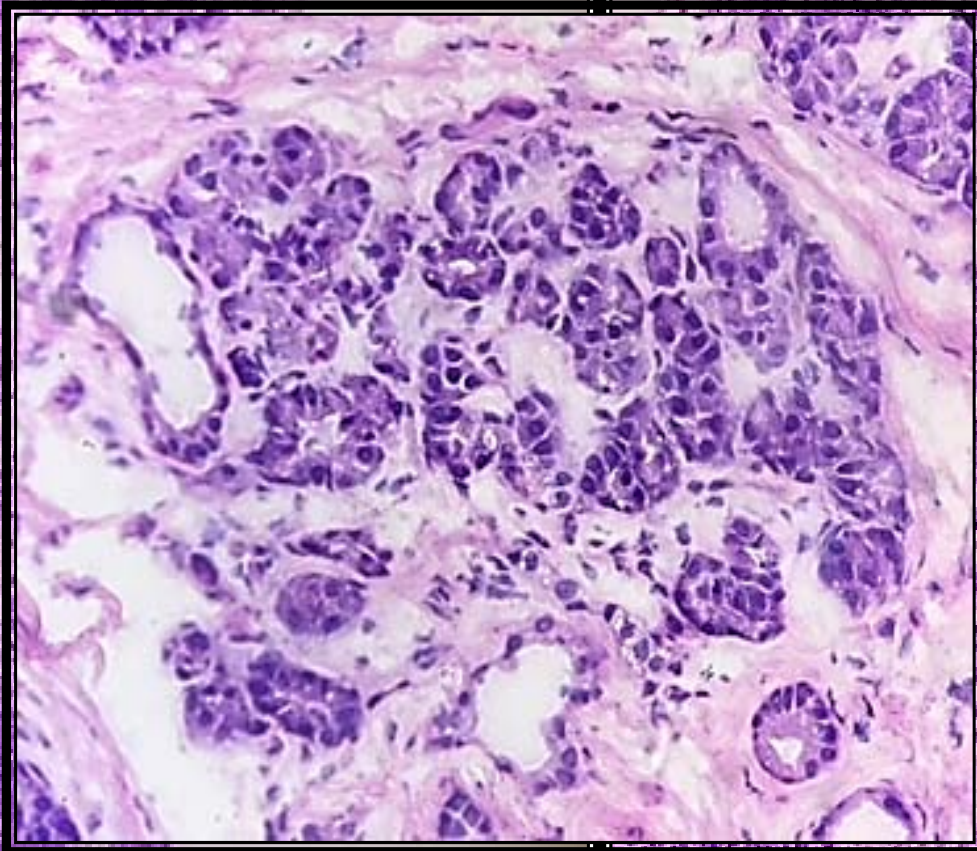
# Mesenteric fat





H&E 4X

H & E 10X





1

# Jejunal nodule

---

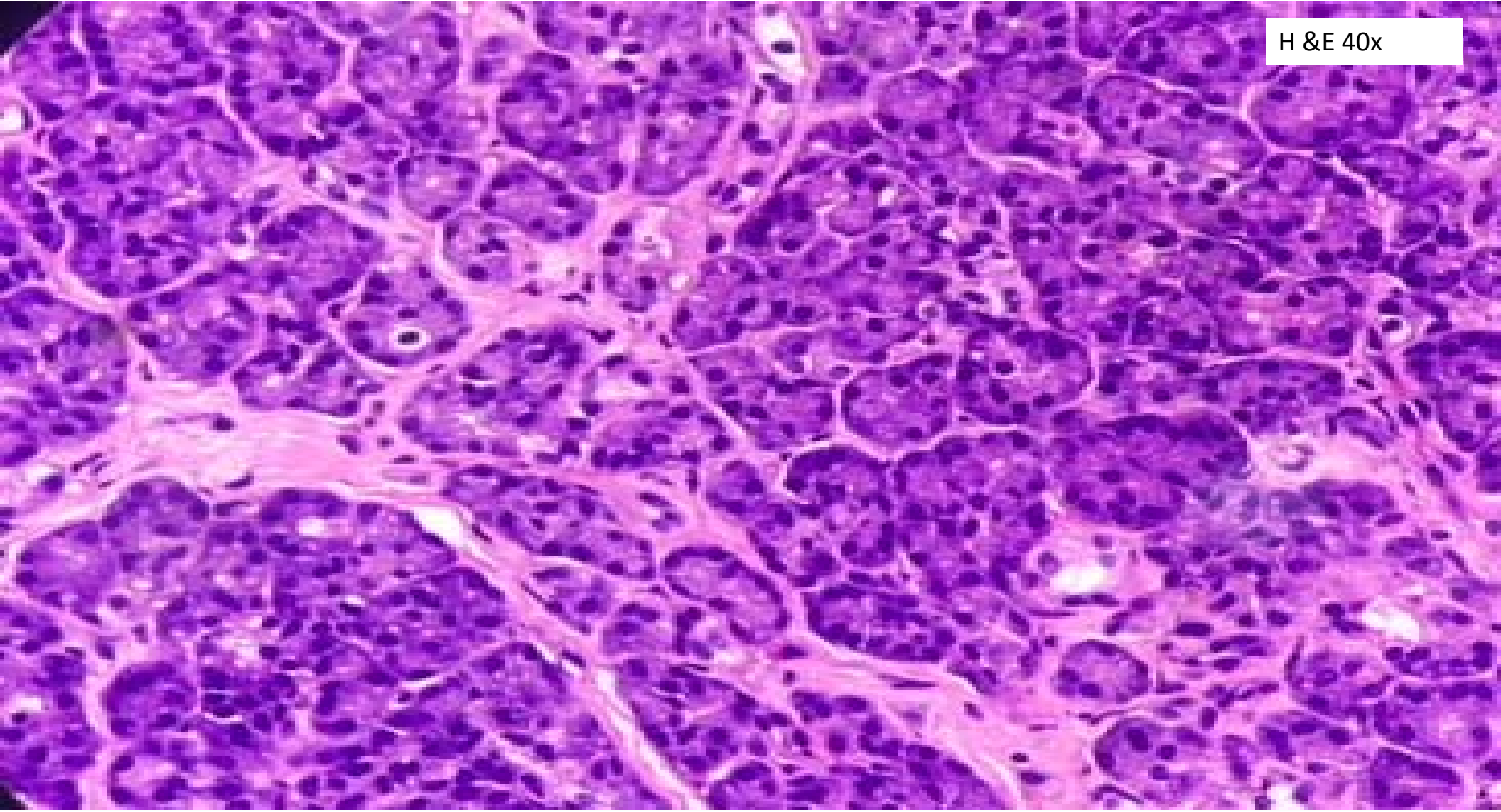
- Lobular architecture
- Regular arrangement of cells
- Bland nuclear features
- No associated stromal reaction



Intraoperative consultation  
**Heterotopic pancreatic tissue**



H & E 40x



# Intraoperative consultation (contd)

---

- **Gall bladder-** Rokitansky Aschoff sinus. No malignancy seen.
- **Lymph nodal mass along small bowel mesentery-** Metastatic adenocarcinoma.



# Pancreatic Heterotopia

- Pancreatic heterotopia , defined as the presence of pancreatic tissue located outside of the anatomical pancreas without any physical or vascular connection to the pancreas itself , is also known as ‘pancreatic choristoma’ , ‘pancreatic rest’ or ‘pancreatic acinar metaplasia’
- The overall incidence ranges widely with publications reporting figures **from 0.5-15% or one in every 500 laparotomies**



# Common sites

---

- Stomach (25- 36%), duodenum (17-36%), and jejunum (15-22%)
- Oesophagus
- Hepatobiliary tract
- Omentum, Meckel's diverticulum
- Lungs, mediastinum
- Fallopian tubes, umbilicus
- Brain

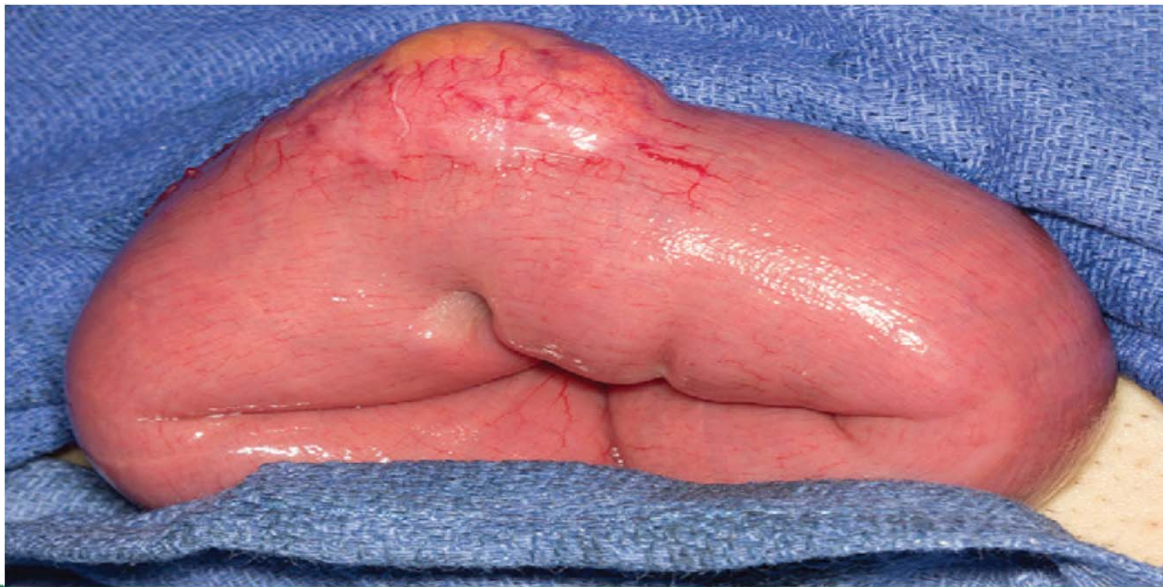




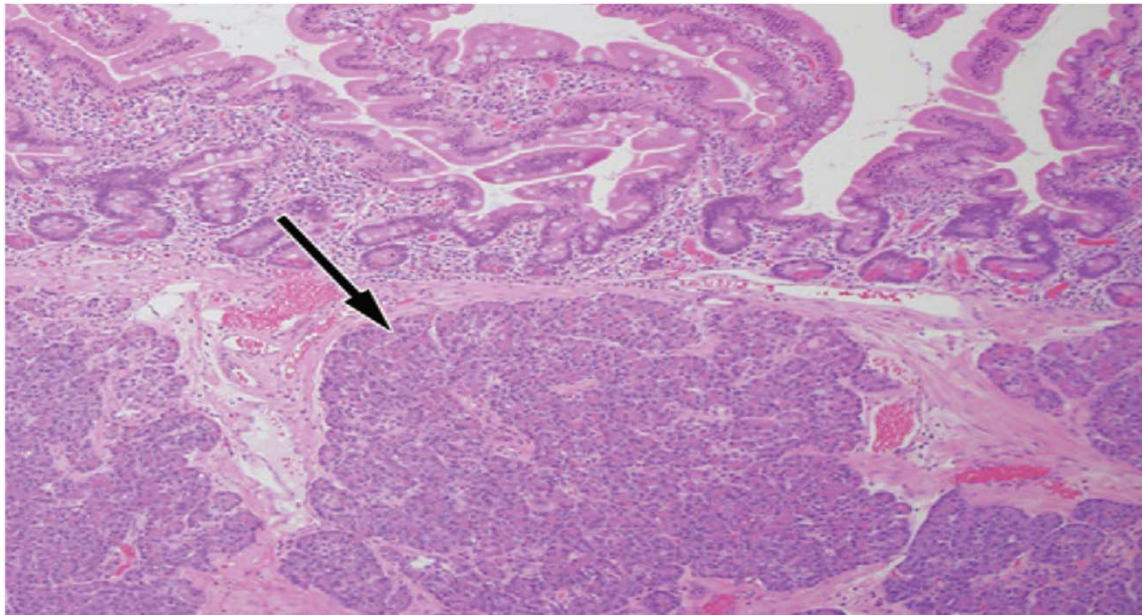
- CT scan – Non specific .
- Difficult to distinguish from gastrointestinal stromal tumours, lymphomas, adenomatous polyps, peptic ulcers or malignancies.



- Gross- Firm, intramural mass that has a lobular shape and a well-defined interface with surrounding tissues. Most lesions (80%) are solitary and < 3 cm.



- HPE- Mucosal inflammation with underlying intramural nodules composed of acini, ducts and/or islet cells



**Table 1: Histologic Classification of Heterotopic Pancreas**

Heterotopic Pancreas Type	Histologic Features Described by Heinrich	Histologic Features Described by Fuentes
Type 1	Heterotopic tissue consists of all the components of normal pancreatic tissue, including acini, ducts, and islet cells	Heterotopic tissue consists of all the components of normal pancreatic tissue, including acini, ducts, and islet cells
Type 2	Heterotopic tissue consists of acini and ducts, with no islet cells	Heterotopic tissue consists of ducts only
Type 3	Heterotopic tissue consists of ducts only	Heterotopic tissue consists of acini only (exocrine)
Type 4	...	Heterotopic tissue consists of islet cells only (endocrine)

Source.—Reference 14.

Note.—The heterotopic pancreas types listed are those originally described by Heinrich in 1909 and modified by Fuentes in 1973.

# Take home message

---

- Pancreatic choristoma, although rare can be seen in laparotomies and can pose problems in frozen section diagnosis.
- Careful observation of the regular, lobular arrangement of cells, cytological features and absence of stromal reaction can aid in accurate diagnosis.



# References

---

- Maryam Rezvani,Christine Menias,Kumaresan Sandrasegaran,Jeffrey D. Olpin,Khaled M. Elsayes,Akram M. Shaaban.Heterotopic Pancreas: Histopathologic Features, Imaging Findings and Complications.[Internet] **2017**; 37:484–499. Available from:[www.rsna.org/education/search/RG](http://www.rsna.org/education/search/RG).
- Rani Kanthan, Jenna-Lynn Senger, Rajni Chibbar, Selliah Kanthan.Pancreatic Heterotopia: Masquerading as Malignancy - A 15-Year Single Institutional Surgical pathology Review. JOP. J Pancreas [Internet] 2015 Jul 08; 16(4):397-402. Available from: <http://www.serena.unina.it/index.php/jop>



**Thank you**

